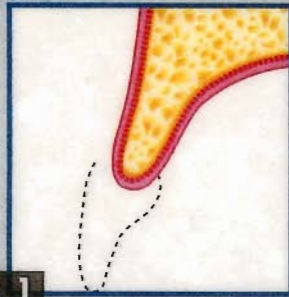


# MENNITT & DALY, PA

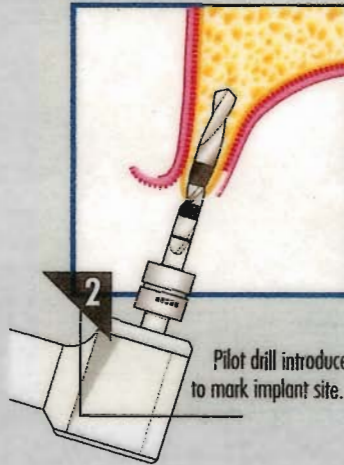
John J. Mennitt, D.D.S. & Jane M. Daly, D.D.S.  
Diplomates of the American Board of Oral and Maxillofacial Surgery

## TUTORIAL SINGLE STAGE RIDGE SPLITTING TECHNIQUE



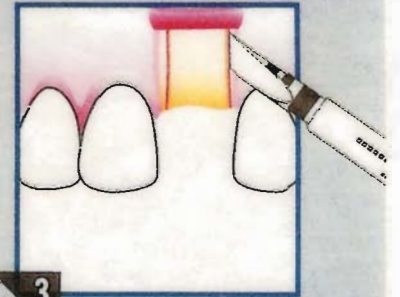
1

Thin anterior maxillary ridge requiring expansion.



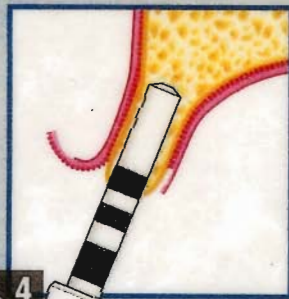
2

Pilot drill introduced to mark implant site.



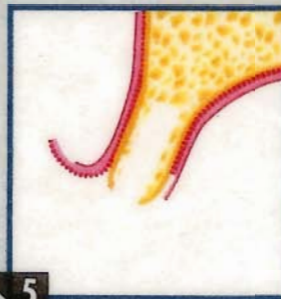3

Vertical osteotomy cuts performed with ridge expanding chisel through the buccal cortex in an oblique fashion followed by horizontal osteotomy at ridge crest.



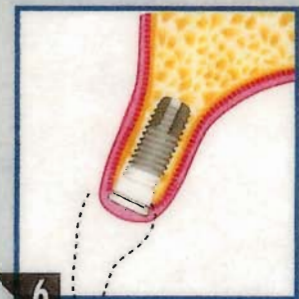4

Ridge expansion technique used to complete implant site.



5

Complete implant osteotomy site.



6

Implant in place; labial ridge preserved.

18109 Prince Philip Drive  
Suite 245  
Olney, MD 20832-1519  
Phone: 301-924-2155  
Fax: 301-924-2376

14300 Gallant Fox Lane  
Suite 220  
Bowie, MD 20715-4033  
Phone: 301-262-1800  
Fax: 301-262-3912